

# RetCam II

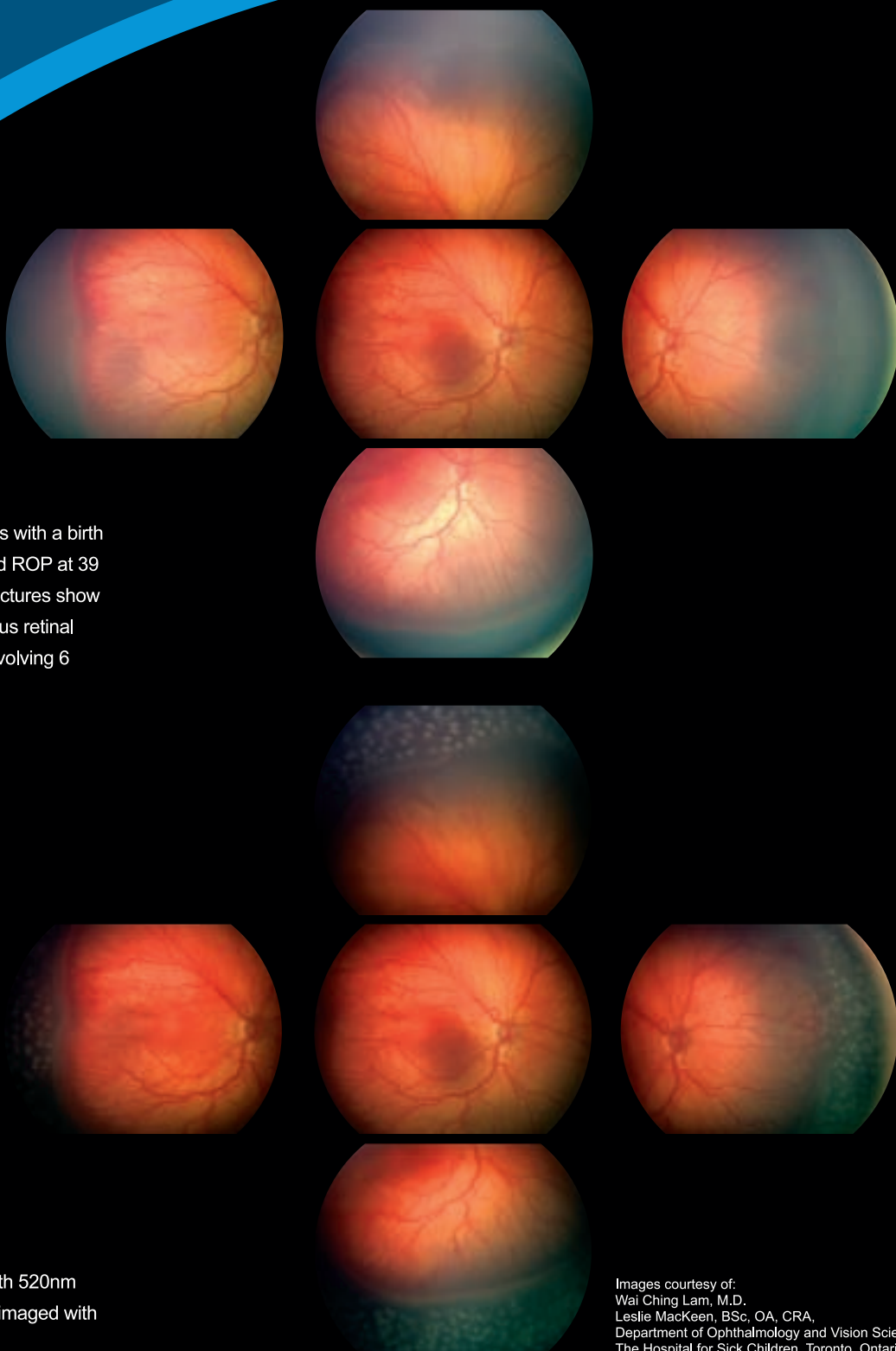
## Retinopathy of Prematurity

### Pre Treatment

This child who was born at 24 weeks with a birth weight of 625 gm, reached threshold ROP at 39 weeks corrected age. The fundus pictures show stage 3 ROP with dilated and tortuous retinal vessels of plus disease in zone II involving 6 contiguous hours.

### Post Treatment

The avascular retina was treated with 520nm transpupillary indirect laser. Patient imaged with 130 degree field-of-view ROP lens.



Images courtesy of:  
Wai Ching Lam, M.D.  
Leslie MacKeen, BSc, OA, CRA,  
Department of Ophthalmology and Vision Sciences,  
The Hospital for Sick Children, Toronto, Ontario, Canada