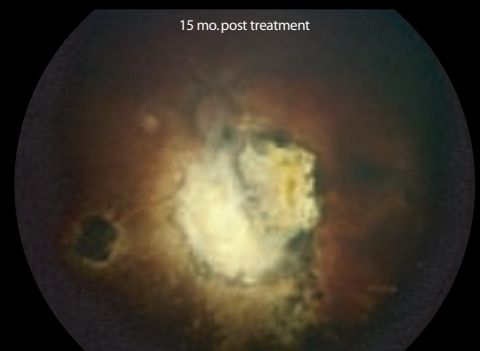
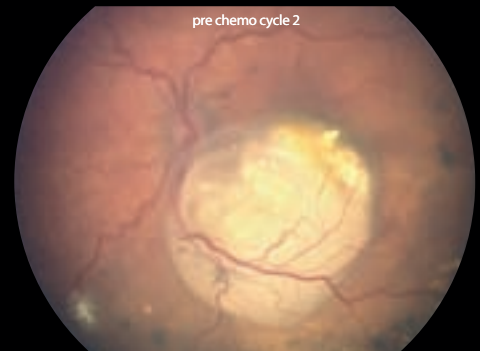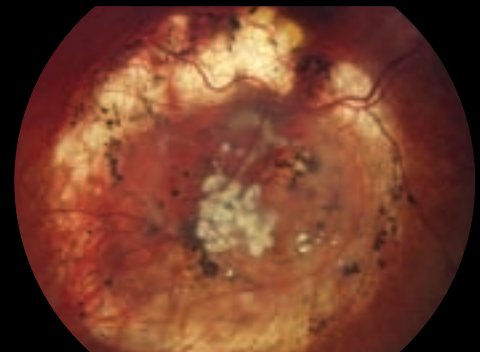
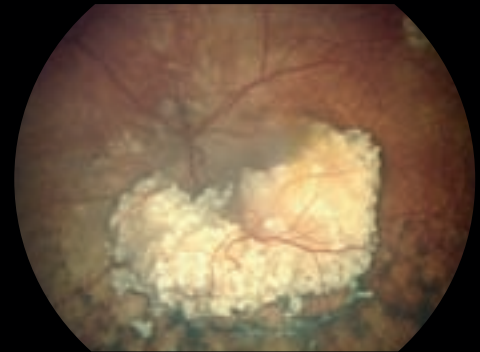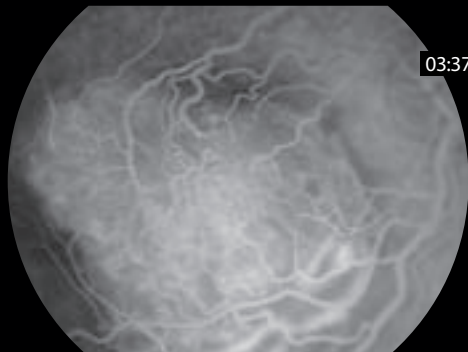
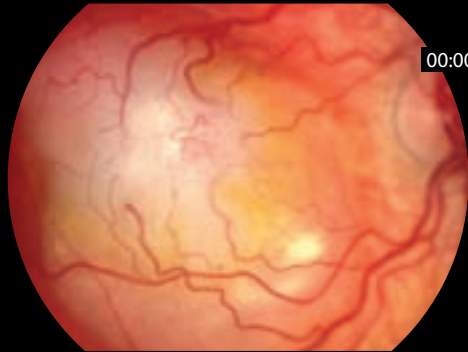


RetCam II

Retinoblastoma



Retinoblastoma

Documenting the course of the disease, visualizing large or peripheral tumours, electronic consultation with international experts as well as many other uses make the RetCam II the “Gold Standard” for Retinoblastoma management.

Images courtesy of:
Leslie MacKeen, BSc, OA, CRA, Department of Ophthalmology and Vision Sciences, The Hospital for Sick Children, Toronto, Canada
Barrett Haik, M.D., St. Jude Children's Research Hospital, Memphis, TN