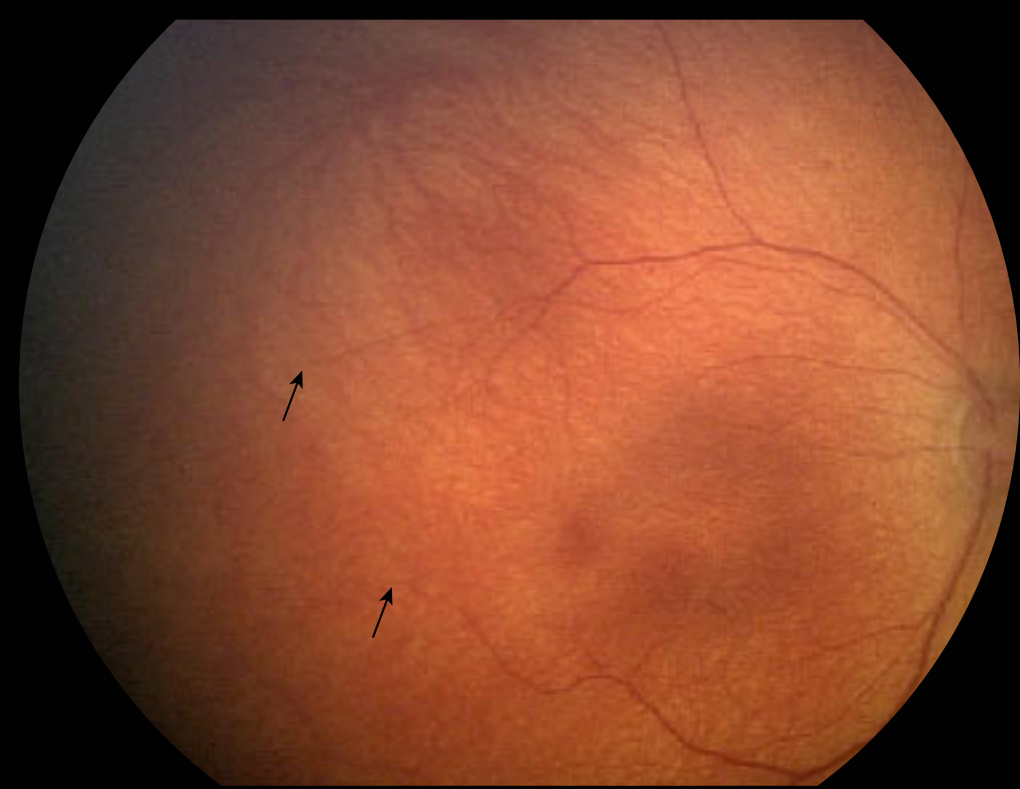

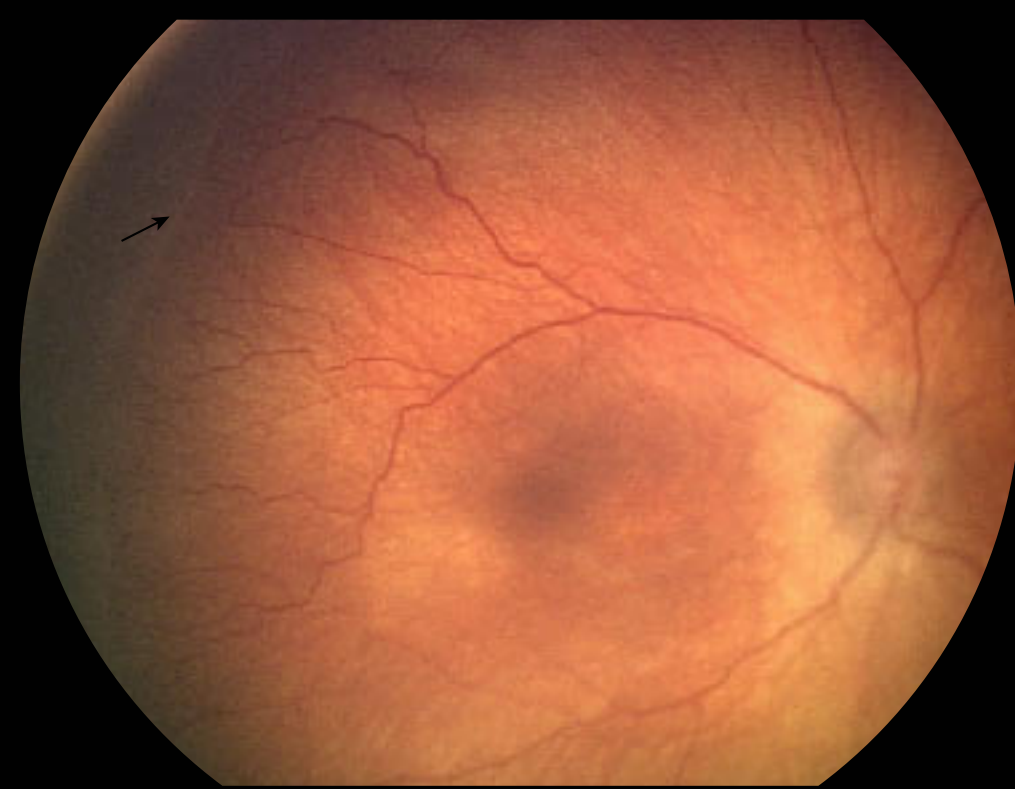
# International Classification of Retinopathy of Prematurity

## Immature Retina



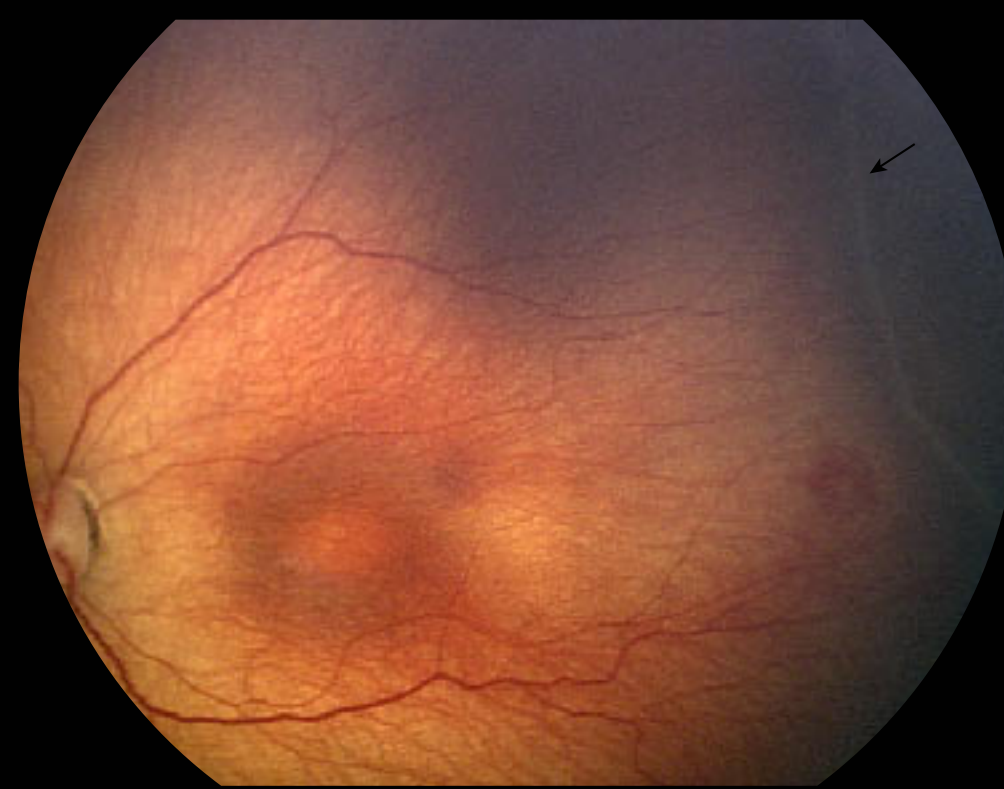retinal vessels taper

## Stage 1: Demarcation Line

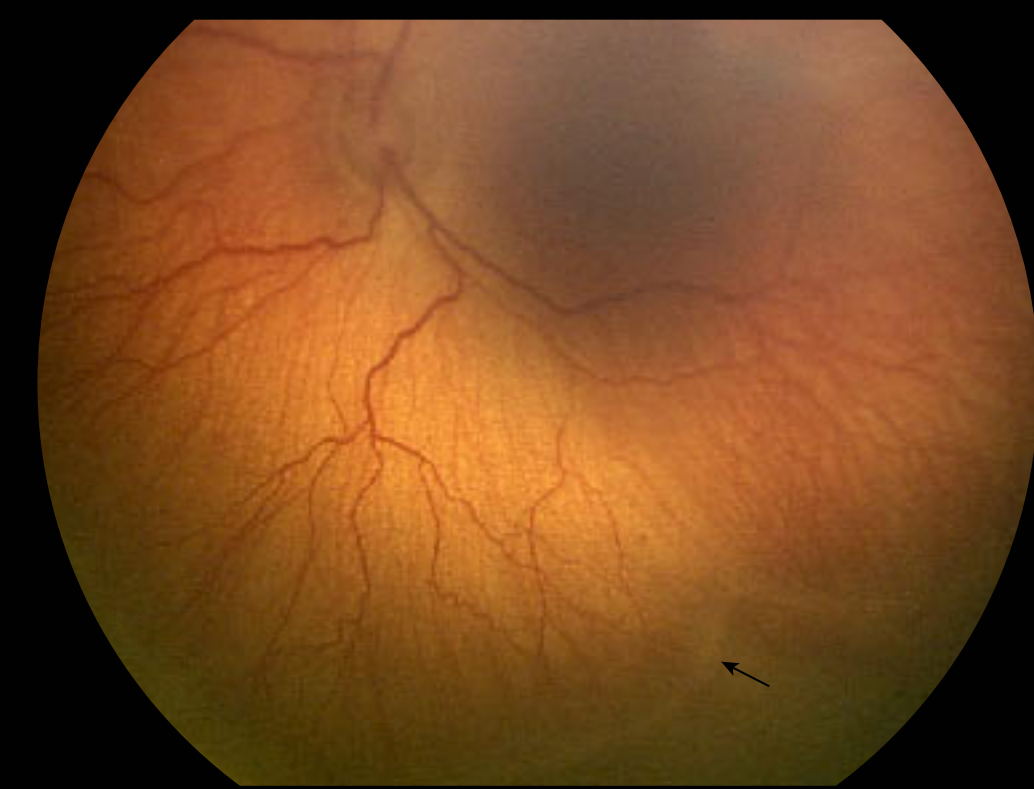


demarcation line separates vascular from avascular retina

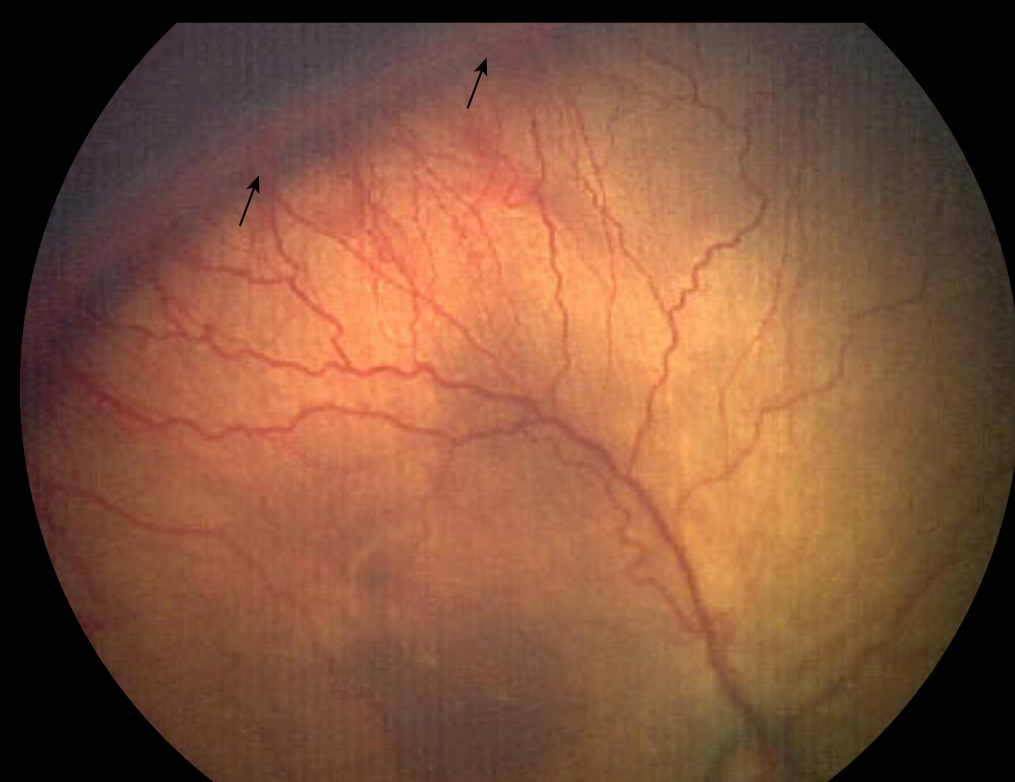
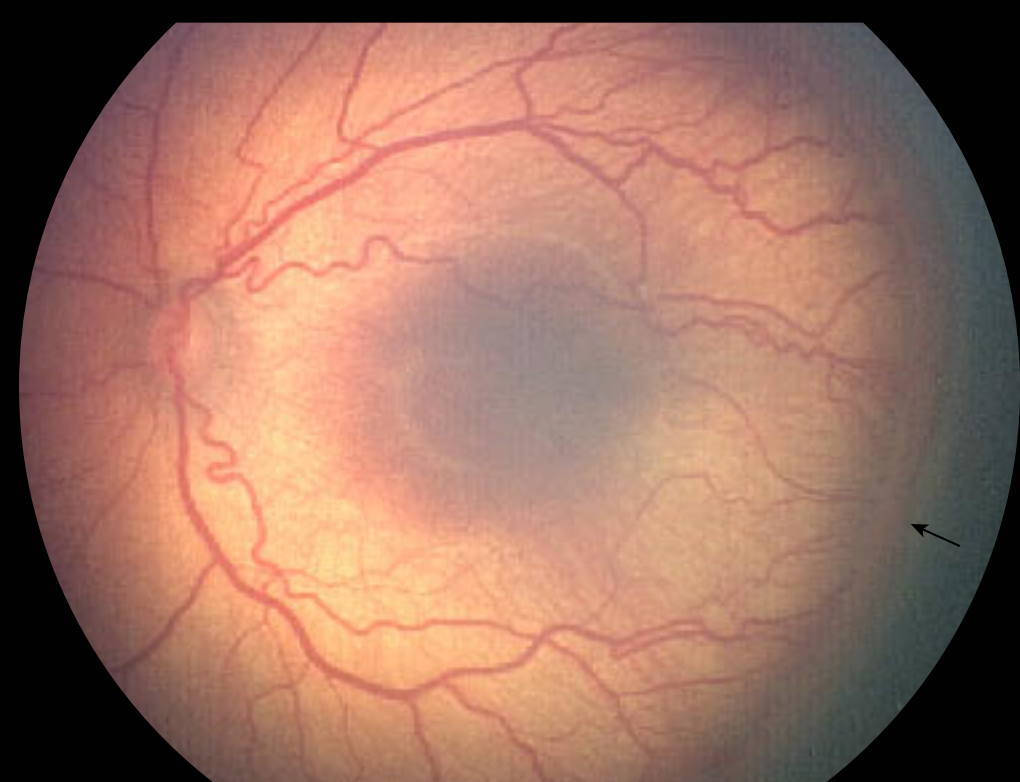## Stage 2: Ridge



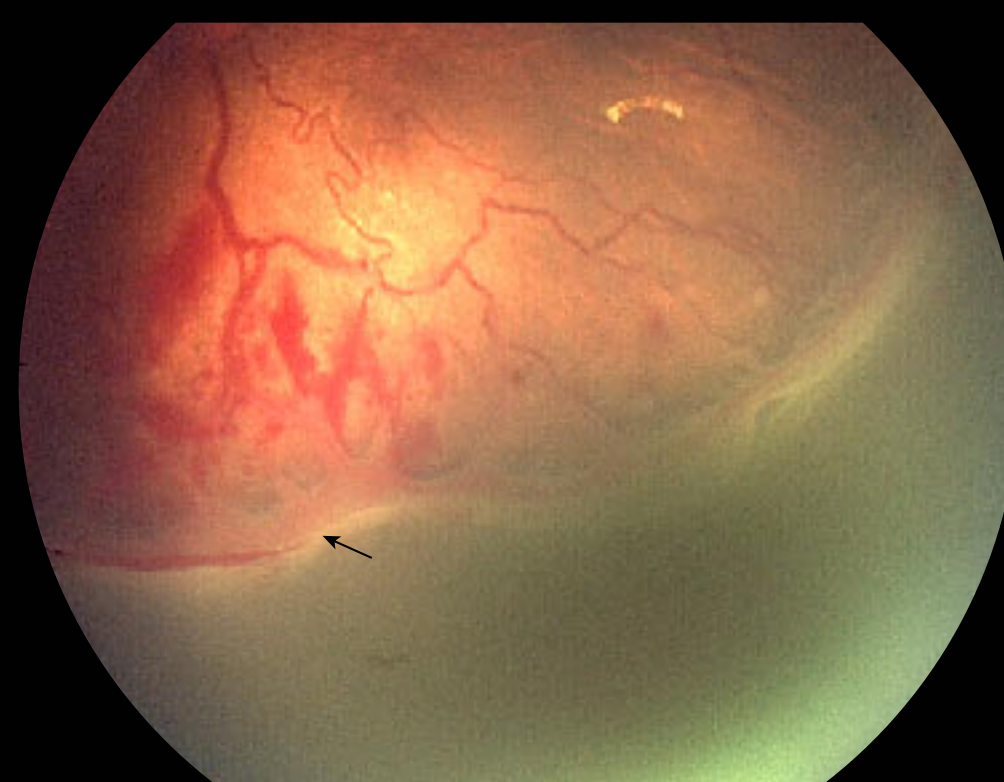
ridge occupies volume



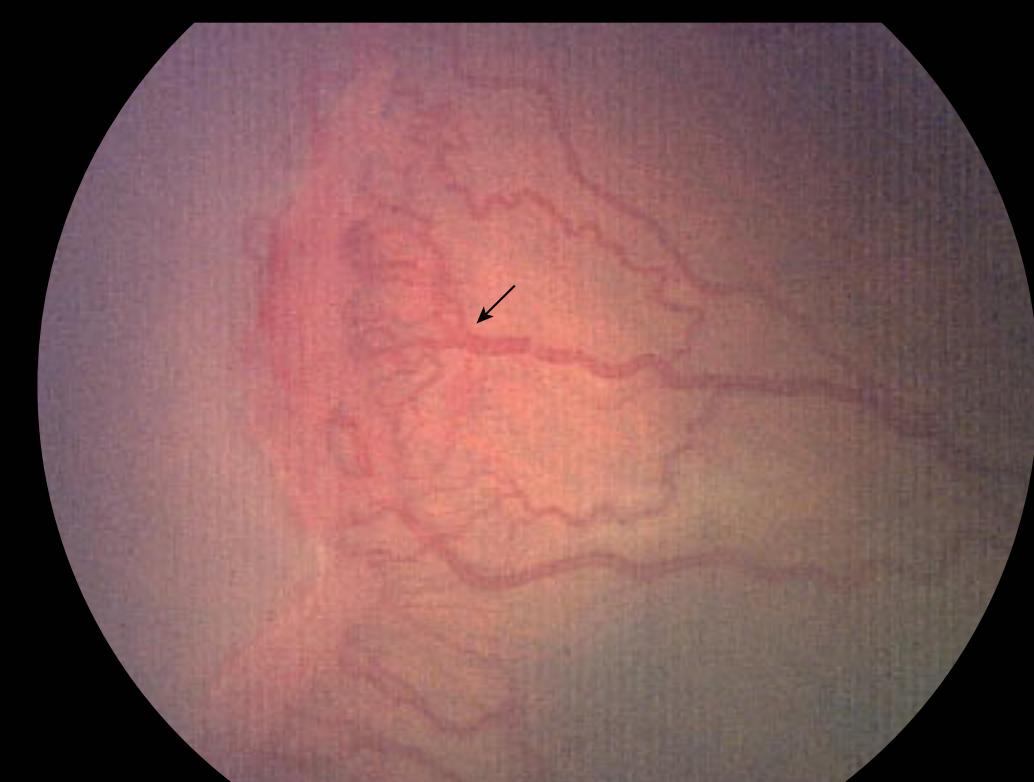## Stage 3: Ridge + Extraretinal Fibrovascular Proliferation (R+EFP)



EFP continuous with posterior ridge causing ragged appearance



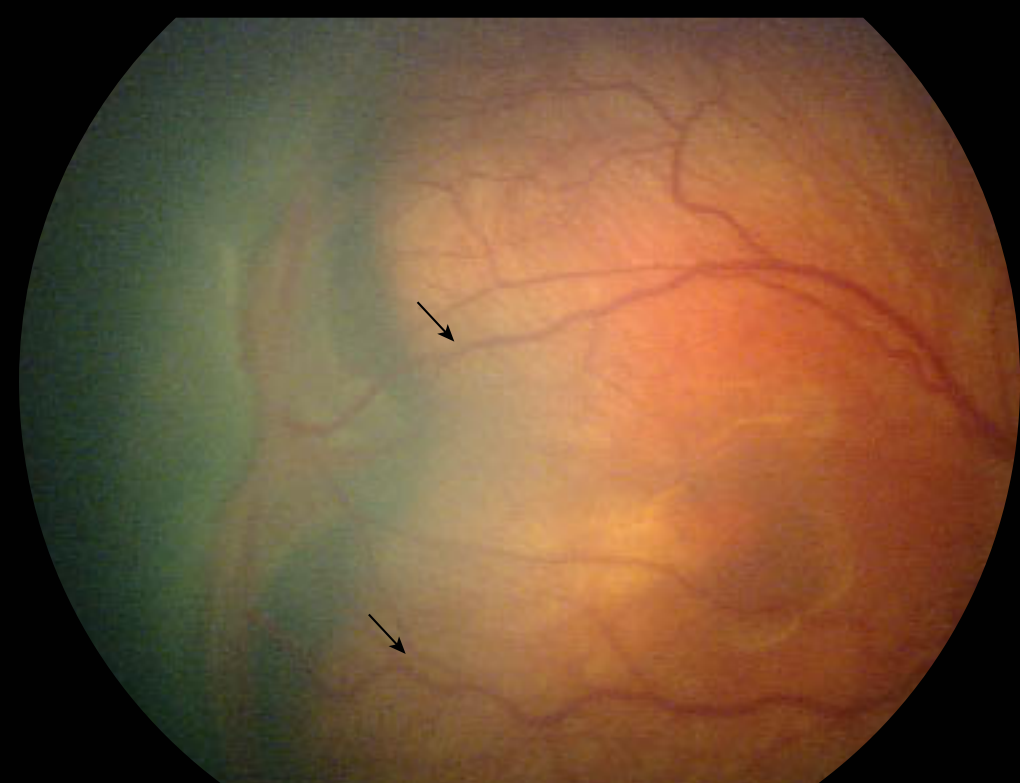
fibrous component of EFP



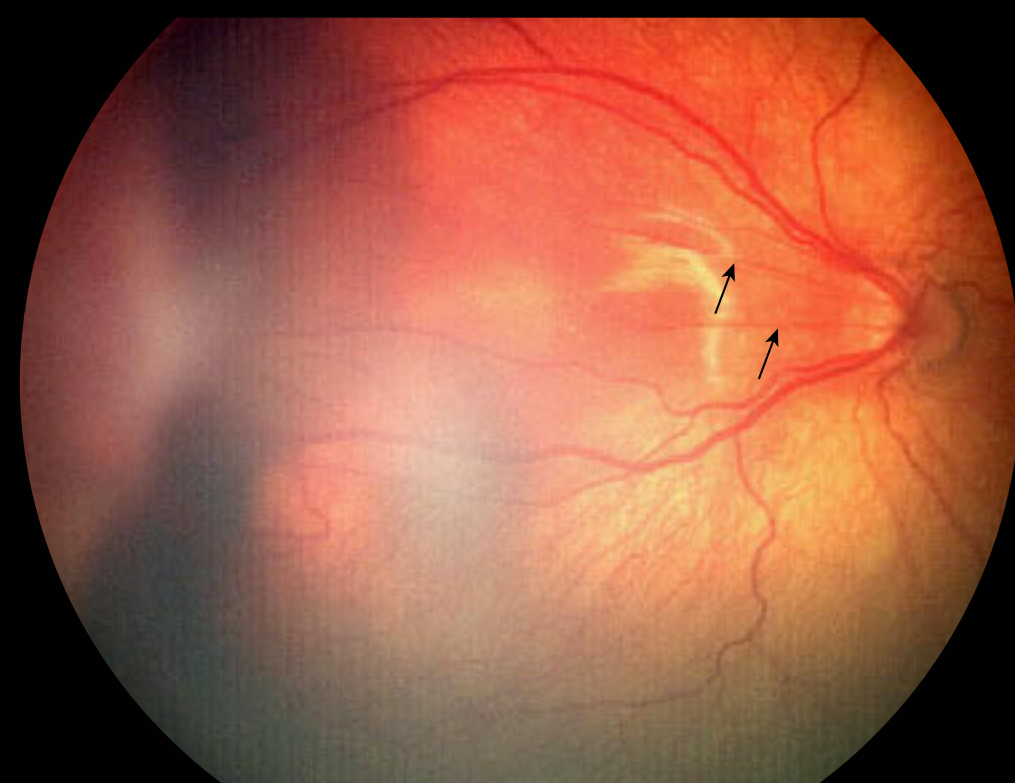
arborization of vessels into EFP lesion

## Stage 4: Partial Retinal Detachment

### 4a: Extrafoveal Partial Retinal Detachment

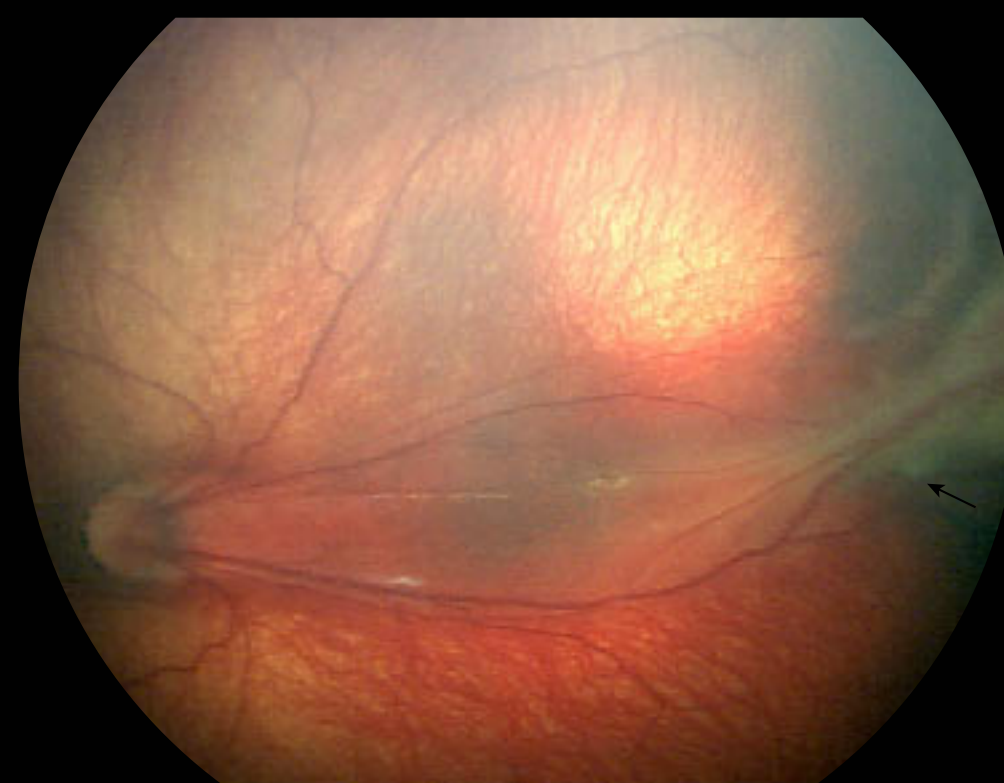


collapse of the temporal arcade angle

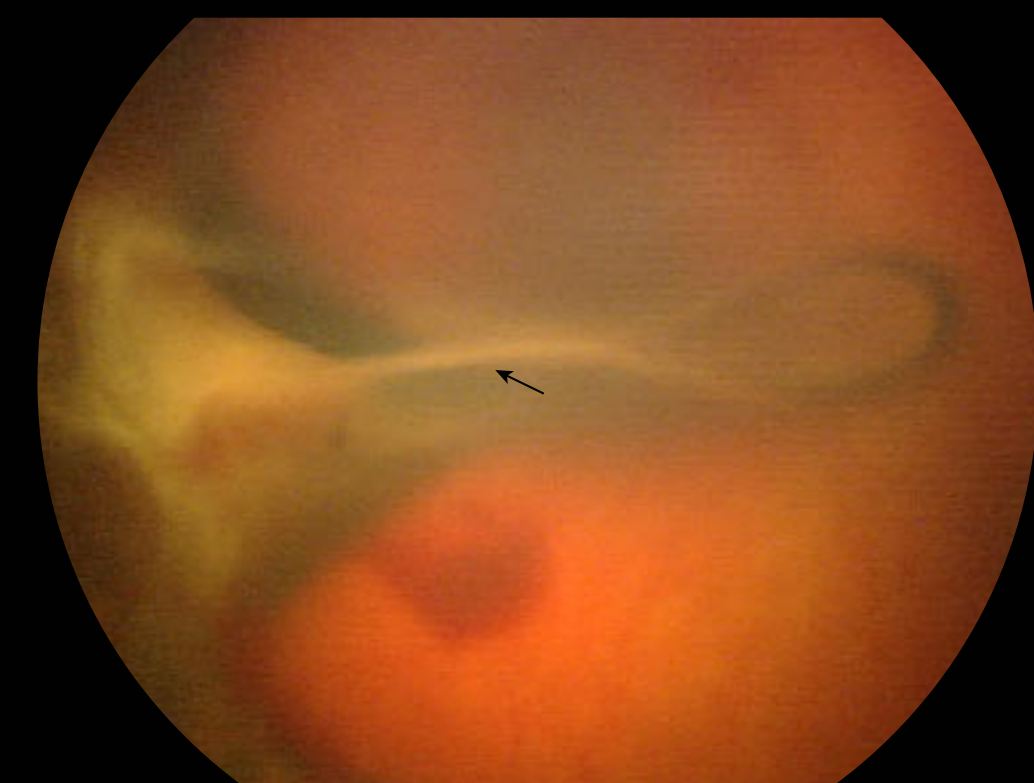

straightening of posterior retinal vessels off the disc

### 4b: Partial Retinal Detachment involving the fovea



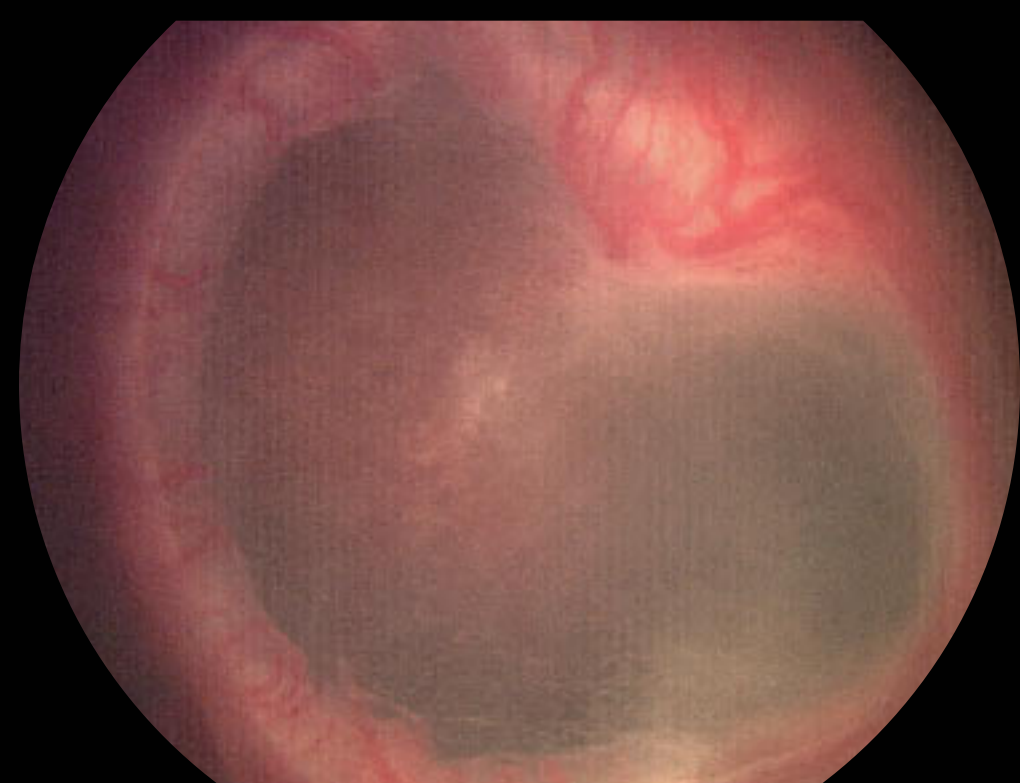
RD begins at fibrovascular connection to vascularized retina



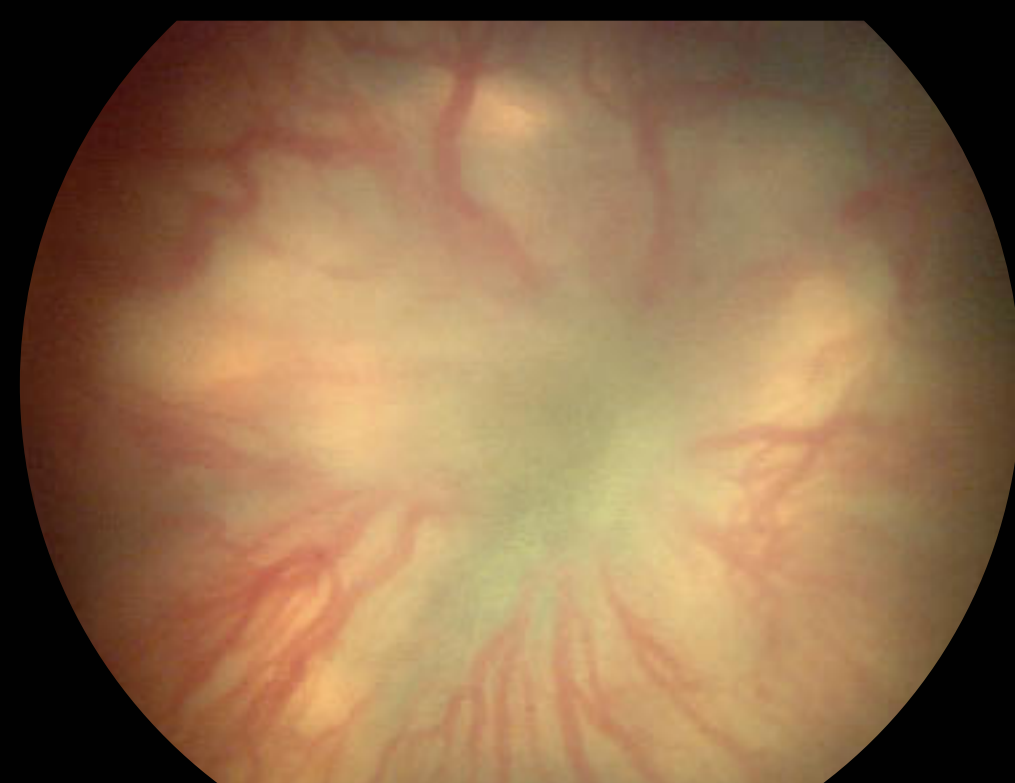cicatrization results in macular fold

## Stage 5: Total Retinal Detachment

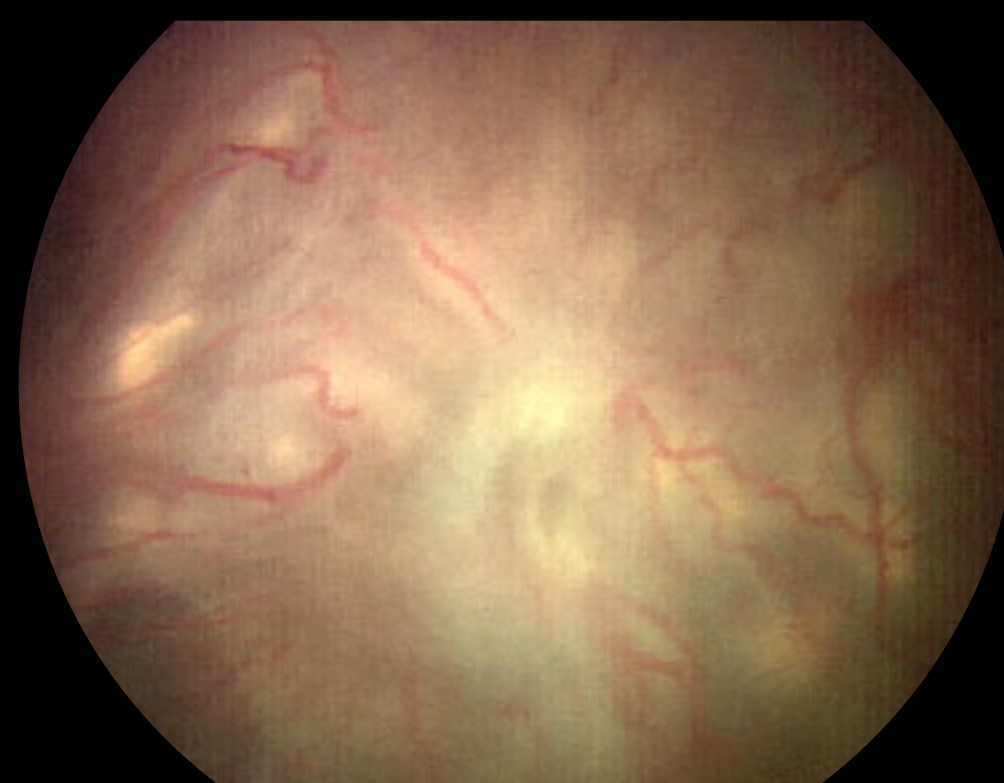### - subdivided by configuration of funnel



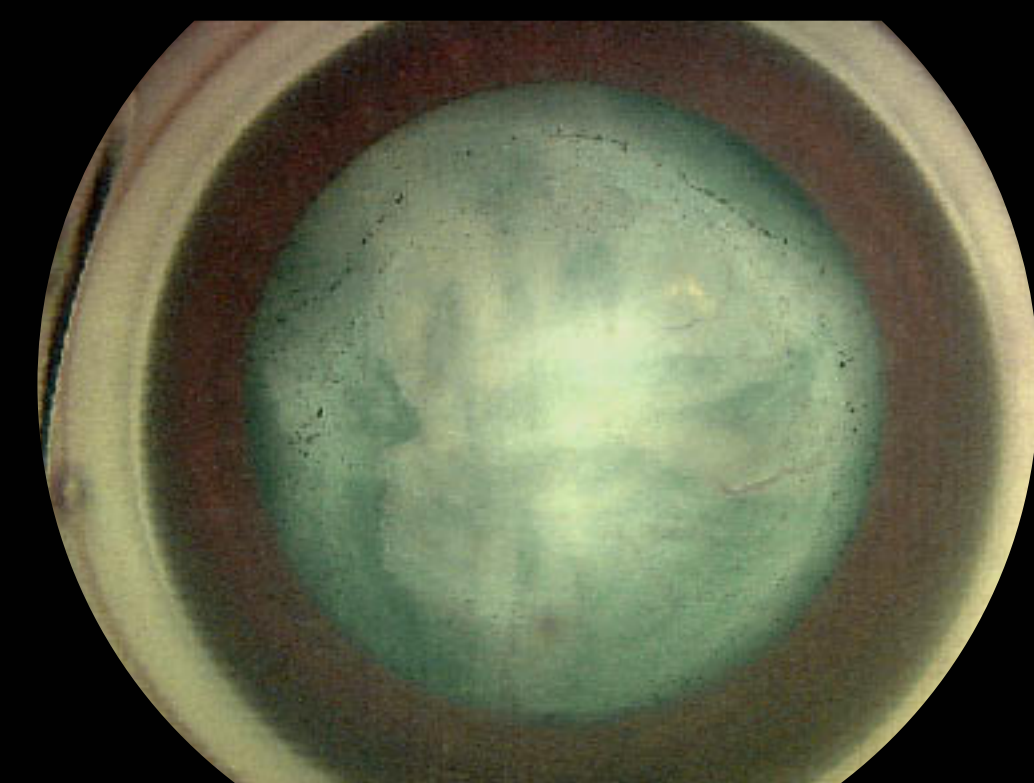
open funnel detachment anteriorly and posteriorly



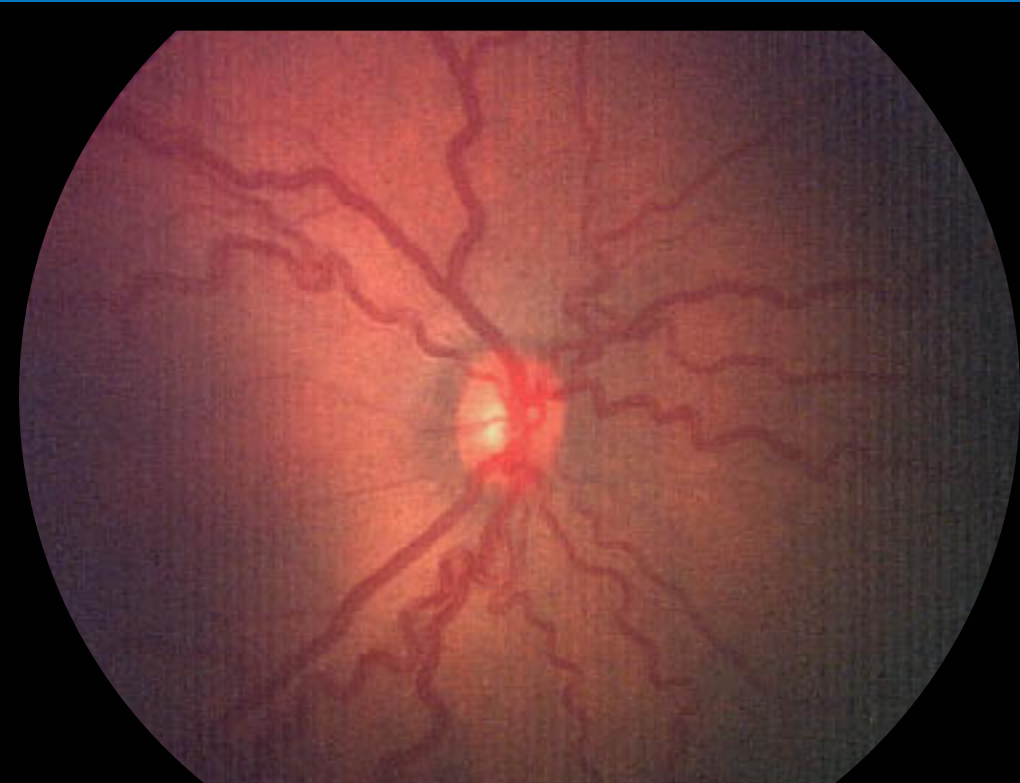open funnel anteriorly



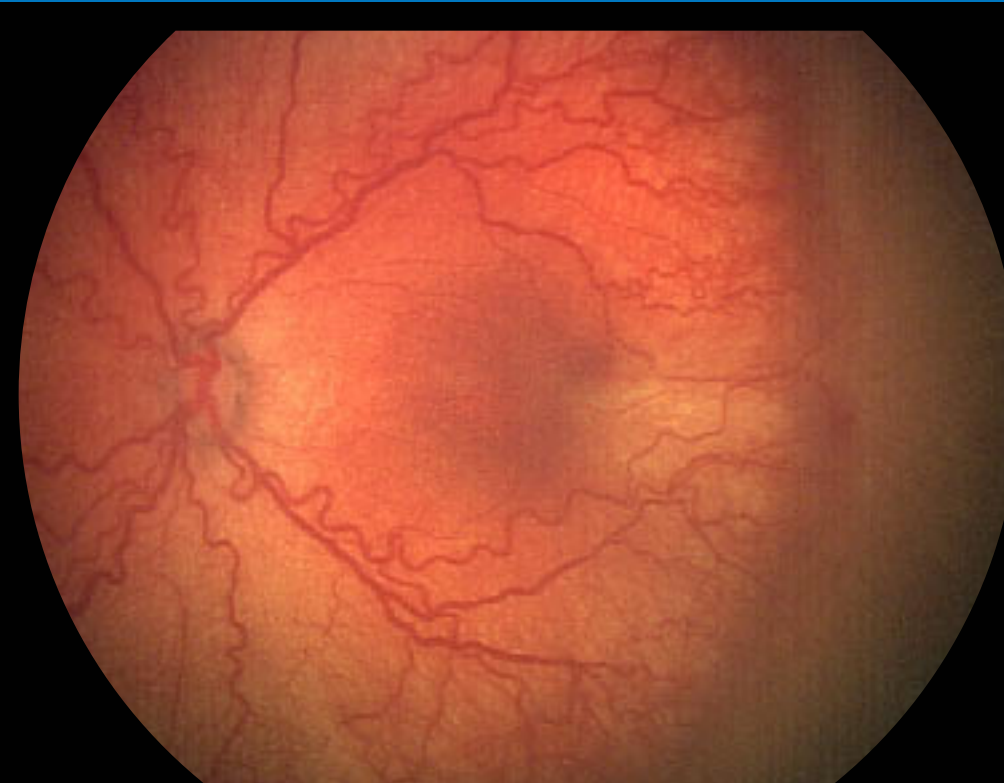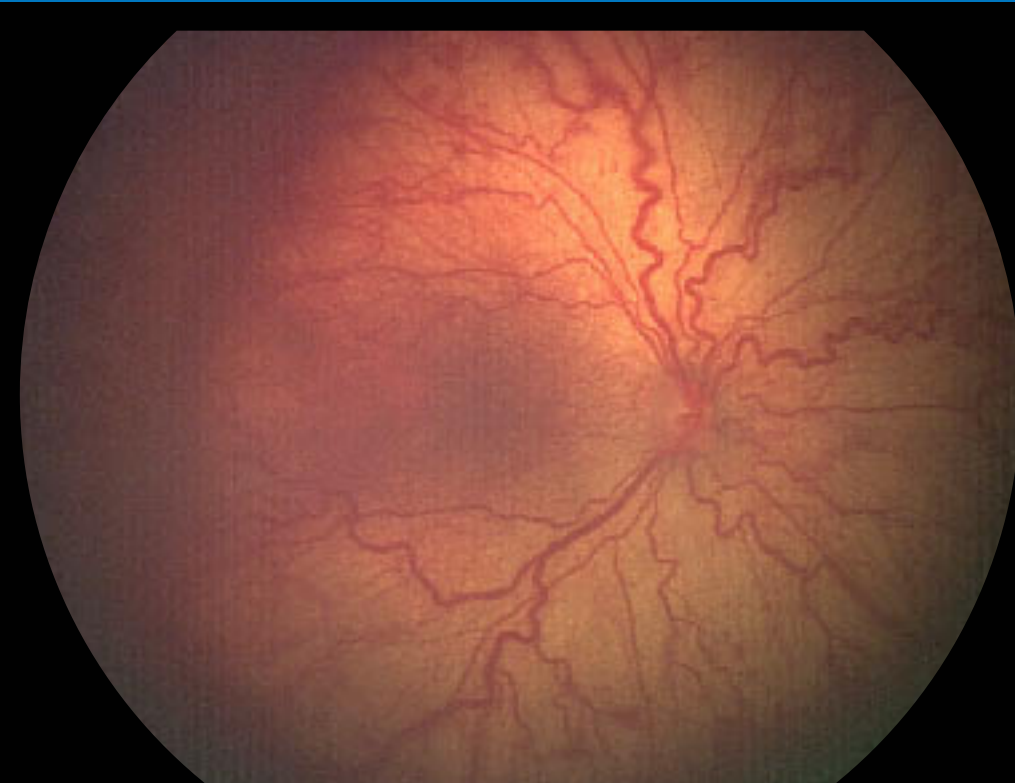closed funnel anteriorly



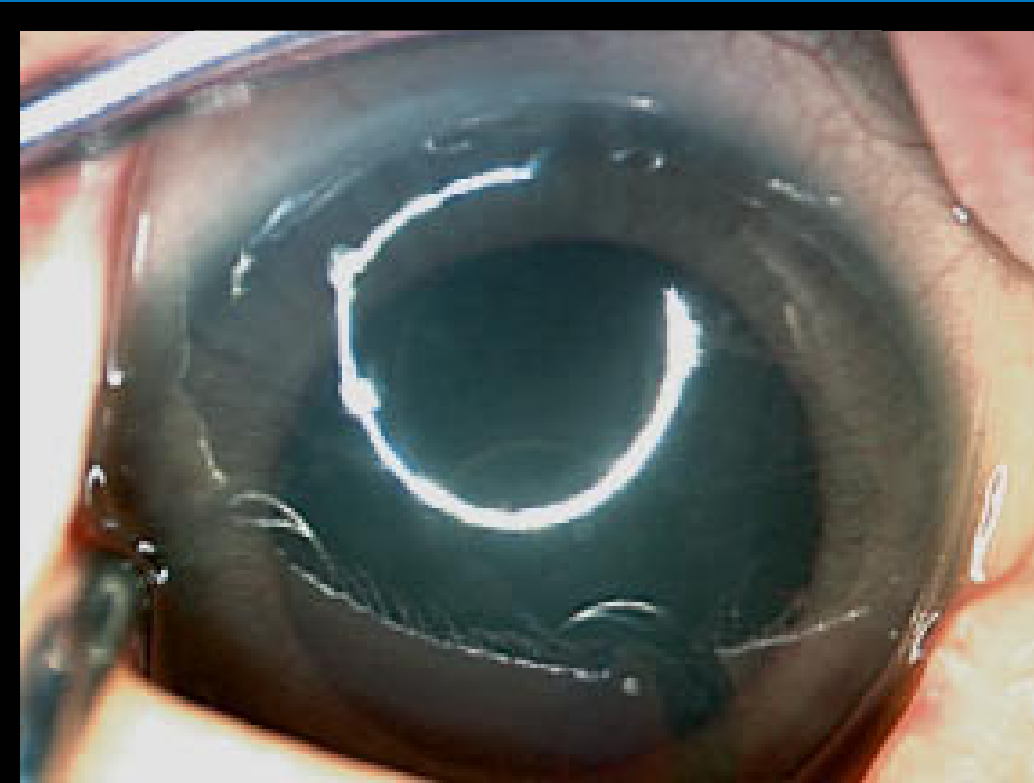
## Plus Disease



venous dilation arteriolar tortuosity



severe plus disease in all 4 quadrants



iris vascular engorgement

**RetCam II**

Your partner in the prevention of blindness just got better...



5775 West Las Positas Boulevard  
Pleasanton, CA 94588-4084  
(800) 215-6005 (925) 463-7984 voice (925) 251-0078 fax  
www.retcam.com

Photography by:

Anna Ellis MD, University of Calgary,  
Alberta Children's Hospital, Calgary, Canada

Leslie MacKeen, BSc, OA, CRA, Department of  
Ophthalmology and Vision Sciences  
The Hospital for Sick Children, Toronto, Canada